

ASTHMA AIRWAY REMODELING

Terrence Shenfield MS, RRT-ACCS, RPFT, NPS, AE-C



- Describe what is asthma remodeling
- Describe the evidence of asthma remodeling
- Describe the pathophysiology of asthma remodeling
- Describe some treatment options

OBJECTIVES



- ▶ First described in 1922 by Hubert and Koessler in cases of fatal asthma
- ▶ Histological abnormalities in the airways due to constant inflammation
- ▶ Long term inflammation leads structural changes of the airways
- ▶ Impacts all cases of asthma in small and large airways (not just severe cases)

WHAT IS ASTHMA AIRWAY REMODELING?



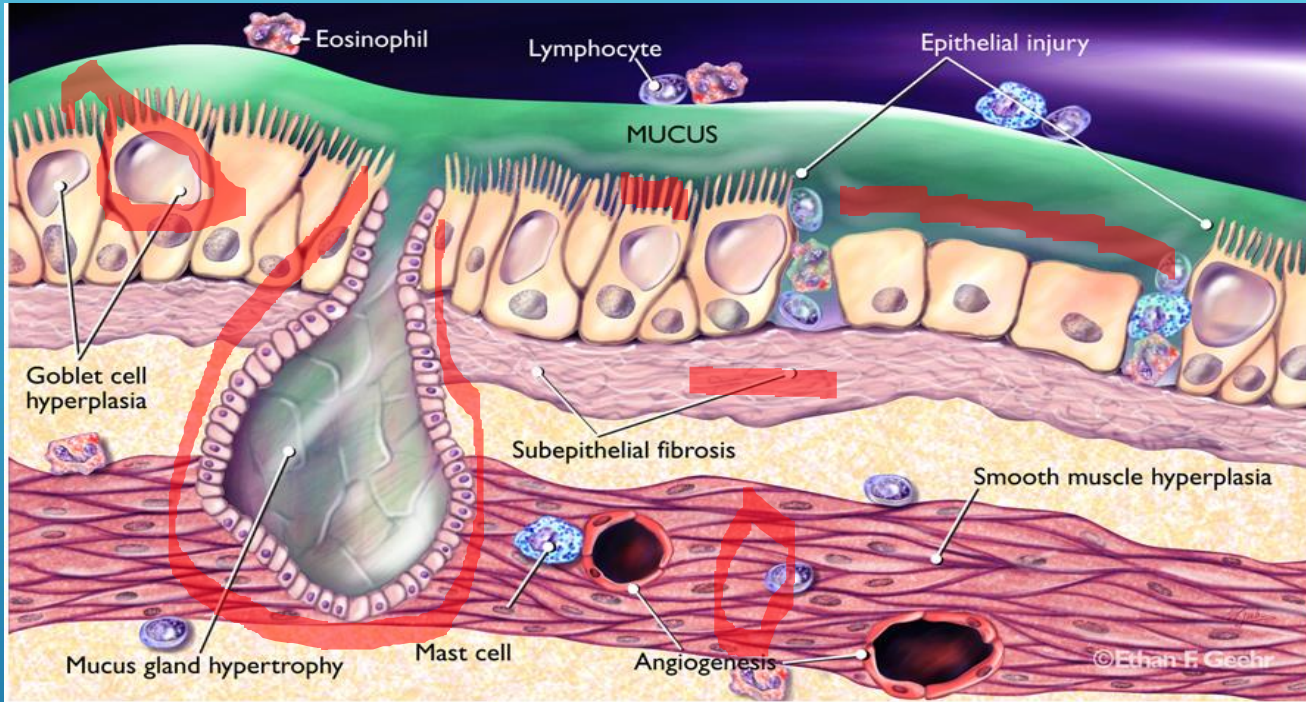
Determining asthma severity and airway remodeling

- FEV1
- Symptom scores (intermittent, mild, moderate, and severe persistent asthma)
- Fixed airway obstruction
- High resolution CT reveals thickened airways that increase in proportion to disease severity
- Bronchial biopsies

Other noninvasive measures may be useful for serial monitoring in severe asthma

DIAGNOSIS





- ▶ Structural changes include
 - ▶ Loss of epithelial integrity
 - ▶ Thickening of basement membrane
 - ▶ Subepithelial fibrosis
 - ▶ Goblet cell hyperplasia
 - ▶ Sub mucosal gland enlargement
 - ▶ Increased smooth muscle mass
 - ▶ Decreased cartilage integrity
 - ▶ Increased airway vascularity

COMPONENTS OF AIRWAY REMODELING



▶ Evidence for remodeling

▶ Peter K. Jeffrey, MD

- ▶ Reviewed the histologic and electron microscopic images
- ▶ Epithelial damage, thickening of the reticular basement membrane, increases in mucus glands and goblet cells, increases in the number and volume of vessels, and increases in airway smooth muscle
- ▶ Reported showing an 18% increase in myofibroblasts 24 hours after allergen challenge
 - ▶ New muscle growth by this mechanism
 - ▶ Convincing evidence for injury, inflammation, and remodeling, with increases in wall thickness, and important changes in myofibroblasts and airway smooth muscle

EVIDENCE OF REMODELING

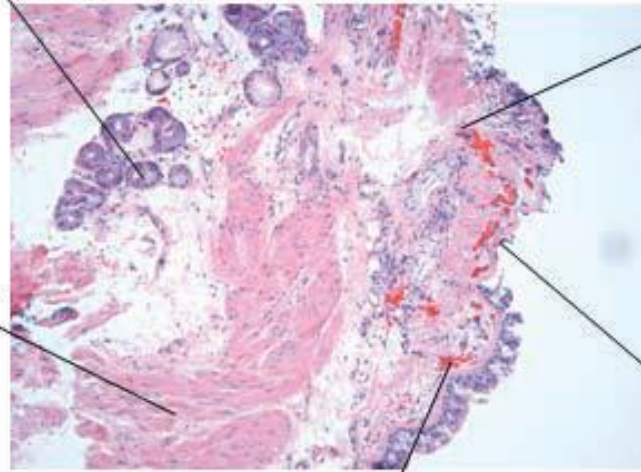


Goblet and mucous gland hyperplasia:

- Increased sputum
- Airway narrowing
- Airway wall thickness

Increased smooth muscle mass:

- Inflammation/fibrosis products
- Asthma severity
- Airway narrowing
- AHR



Subepithelial fibrosis:

- Severity of asthma
- AHR
- Protective against BC (?)

Epithelial alteration:

- AHR
- Decrease protective barrier

Angiogenesis:

- Airway wall oedema
- Mediators delivery

FEATURES OF AIRWAY REMODELING



- ▶ Duration of asthma
- ▶ Greater use of medications
- ▶ Chronic inflammatory process which leads to activation of
 - ▶ Eosinophils
 - ▶ Neutrophils
 - ▶ Mast cells

WHY DOES THIS OCCUR?

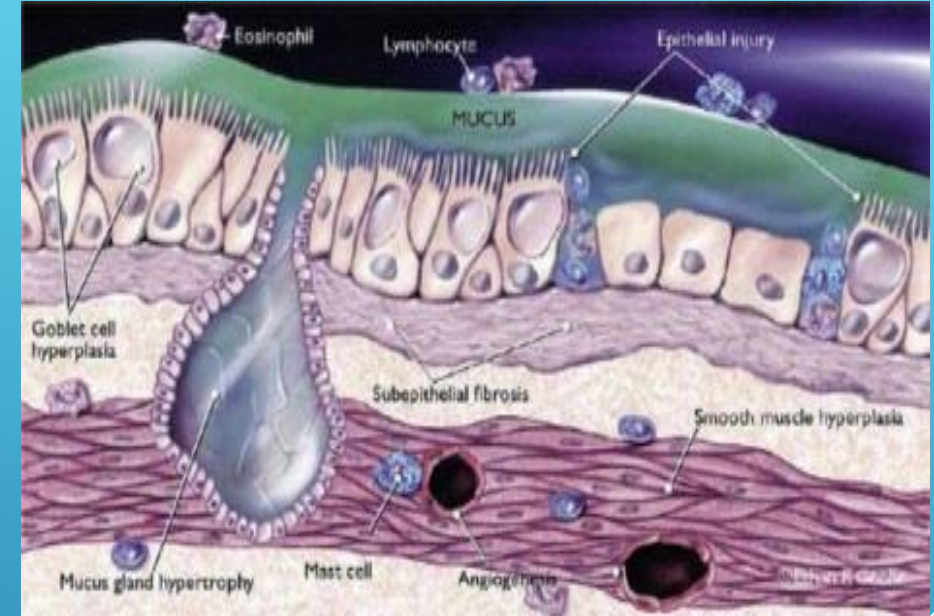


- ▶ Destruction of ciliated cells
- ▶ Epithelial shedding
- ▶ Goblet hyperplasia
 - ▶ Increased sputum
- ▶ Clinical implications
 - ▶ Loss of physical barrier against inhaled allergens
 - ▶ Loss of epithelial surface area
 - ▶ Airway narrowing
 - ▶ Airway wall thickness

EPITHELIAL ALTERATION AND CLINICAL IMPACT



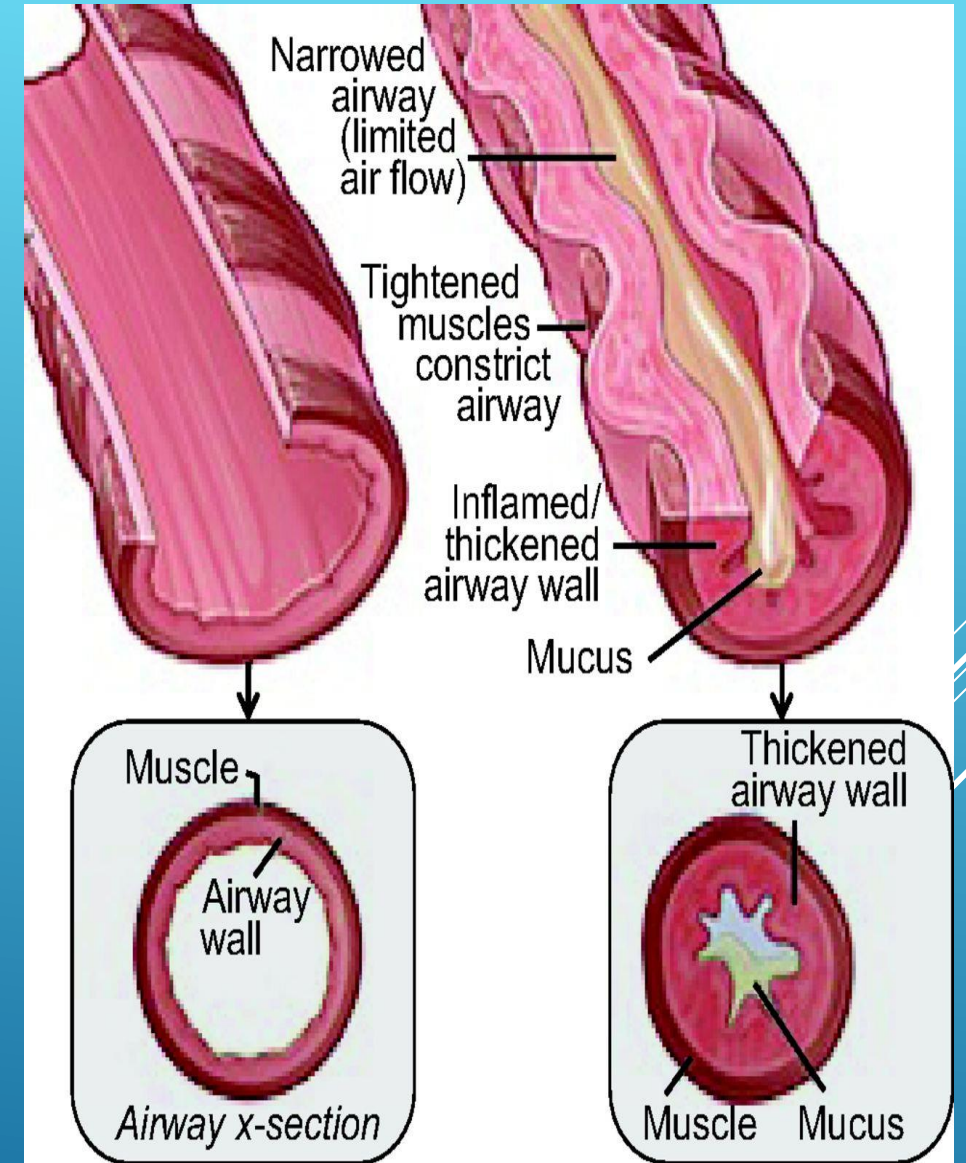
- ▶ Subepithelial fibrosis
 - ▶ Reported in all cases of asthma
 - ▶ Basement membrane thickening
 - ▶ Fibrosis resulting in increased deposition of extra-cellular matrix proteins by fibroblasts
 - ▶ Associated with asthma severity and increased airway wall thickness



SUBEPITHELIAL FIBROSIS AND CLINICAL IMPACT



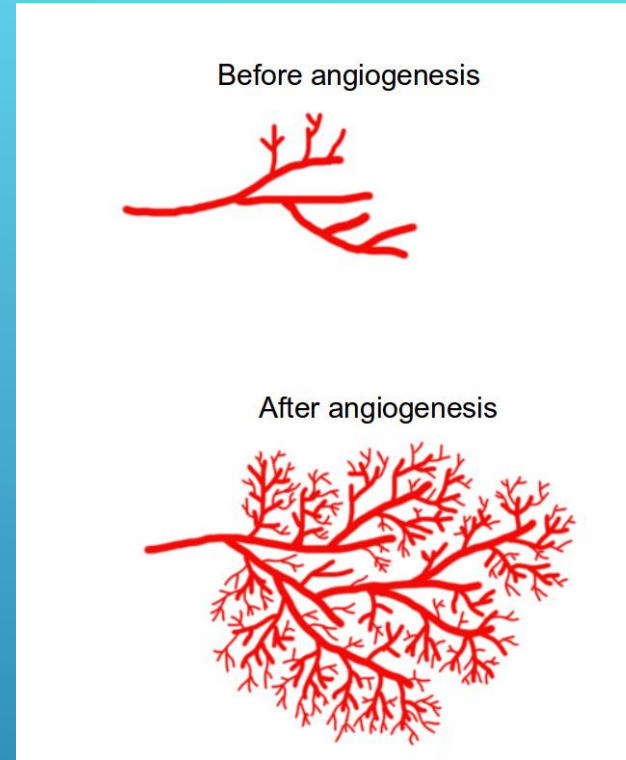
- ▶ Respiratory airway smooth muscle is the critical modulator of airway tone
- ▶ Asthmatic airways
 - ▶ Smooth muscle mass is increased due to increase in the size (hypertrophy) and number (hyperplasia)
 - ▶ Smooth muscle cells migrate to the subepithelial area of the asthmatic airways increasing in size
 - ▶ Smooth muscle cells participate in the inflammatory and remodelling processes
 - ▶ Release of proinflammatory mediators such as cytokines and chemokines
 - ▶ Chemokines have the ability to induce human airway smooth muscle cell migration and to increase their contractility
 - ▶ Contribute to the overall airflow obstruction in these patients



INCREASED SMOOTH MUSCLE MASS AND CLINICAL IMPACT



- ▶ Vascular alterations occur leading to increased size of airway wall vessels and angiogenesis
- ▶ Airway wall edema
 - ▶ Changes in the airway wall
 - ▶ Greater expression of vascular endothelial growth factor
- ▶ Clinical consequences of airway wall angiogenesis
 - ▶ Reduced airway caliber via airway wall edema
 - ▶ Increased inflammatory response and remodeling

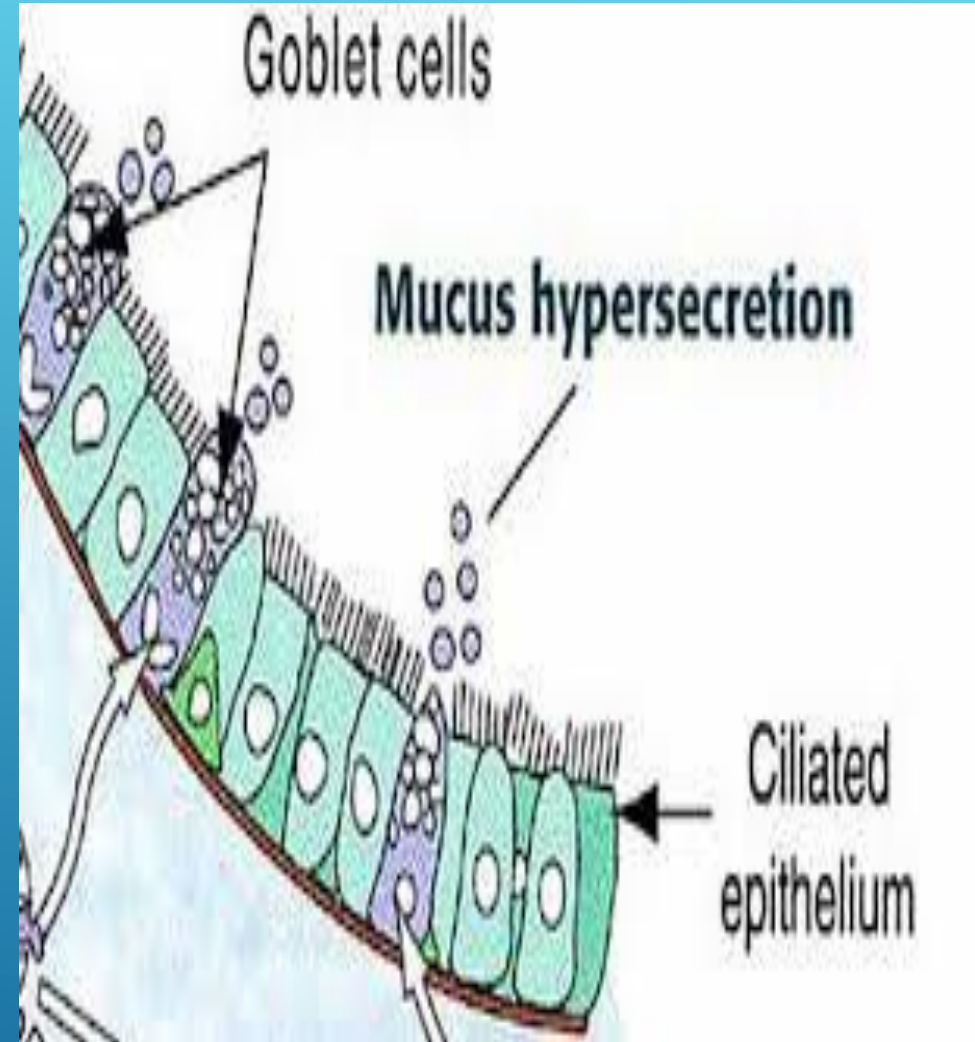


ANGIOGENESIS AND CLINICAL IMPACT



- ▶ In asthmatic adults and children
 - ▶ Goblet cell hyperplasia and submucosal gland hyperplasia are seen
 - ▶ Consequences of these abnormalities mostly result
 - ▶ Increased sputum production
 - ▶ Airway narrowing due to sputum secretion
 - ▶ Increased airway wall thickness

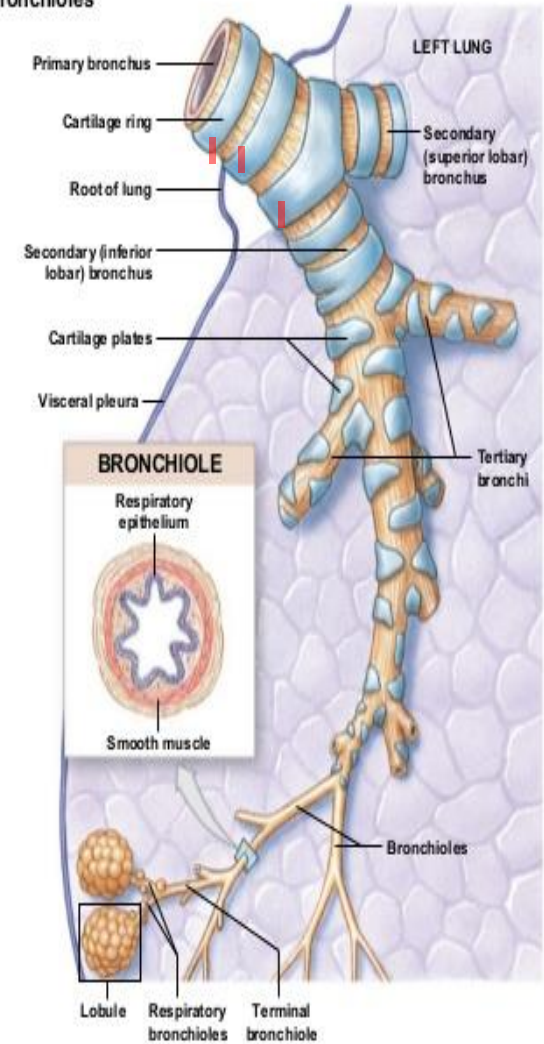
GOBLET CELL AND MUCOUS GLAND HYPERPLASIA AND CLINICAL IMPACT



- ▶ Airway cartilage is an important determinant of airway wall stiffness and integrity
- ▶ Decreased cartilage volume and increased cartilage proteoglycan degradation
- ▶ Reduced cartilage integrity results in a more bronchoconstriction

LOSS OF CARTILAGE INTEGRITY AND CLINICAL IMPACT

Figure 24.11 Bronchi and Bronchioles



© 2012 Pearson Education, Inc.



- ▶ Asthmatic individuals are characterized by airway inflammation:
 - ▶ Eosinophils, mast cells and lymphocytes migrate to airways
 - ▶ Release of mediators
 - ▶ Bronchoconstriction, mucous secretion and remodeling
 - ▶ Correlates with airway hyper responsiveness(AHR)
 - ▶ Mediators such as IL-11 and IL-17 have potent remodeling properties
 - ▶ Histamine participates in airway remodeling through increased fibroblast

INFLAMMATION AND CLINICAL IMPACT



- ▶ Effect of airway remodeling on lung function
 - ▶ Structural alterations and inflammatory process are related to the magnitude of functional abnormalities in asthma
 - ▶ Airway remodelling has significant effects on lung function and is believed to be responsible for the chronicity of asthma

LUNG FUNCTION AND LONG TERM CONSEQUENCIES



- ▶ Allergic rhinitis is a risk factor for asthma and airway remodelling
- ▶ Patients with rhinitis have a three-fold chance of getting asthma
- ▶ Rhinitis control improves asthma control
- ▶ Montelukast and antihistamines are the mainstay therapy in rhinitic subjects with improving asthmatic severity and management

ALLERGIC RHINITIS AND REMODELING



- ▶ Immunotherapy is reserved for moderate to severe allergic rhinitic subjects
 - ▶ Immunotherapy reduces inflammatory cell recruitment and activation
 - ▶ Reducing allergen sensitivity leads not only to relief of rhinitis but also helps control asthma
 - ▶ Beneficial effects of rhinitis treatment on asthma is reduction of airway inflammation
 - ▶ Whether reduced inflammation leads to diminished airway remodeling and less asthma expression is still unknown
 - ▶ More research is required

IMMUNOTHERAPY AND ALLERGIC RHINITIS



- ▶ Corticosteroids
 - ▶ Control of persistent asthma is best achieved early with ICS use
 - ▶ ICS have the potential to influence remodeling of airways
 - ▶ Inflammatory mediators can be reduced by use of corticosteroids
 - ▶ Antiproliferative effect of corticosteroids
 - ▶ Benefit asthmatic patients by reducing smooth muscle mass
- ▶ ICS form the basis of asthma therapy and the best way to control airway inflammation
- ▶ More studies are to be performed as there isn't quite convincing evidence of its effect on remodelling

CORTICOSTEROIDS AND AIRWAY REMODELING



- ▶ Montelukast is a leukotriene receptor antagonist is commonly used in asthma therapy and rhinitis
- ▶ Asthmatic patients with nasal polyposis treated with Montelukast
 - ▶ 70% improvement in nasal symptoms
 - ▶ 60% to 90% improvement in clinical asthma scores
- ▶ Montelukast decreases sputum eosinophils after allergen challenge
- ▶ Anti-inflammatory effects may play an important role in the pathogenesis of airway remodeling

ANTAGONIST LEUKOTRIENES (VERY PROMISING)



- ▶ Montelukast has been shown to significantly inhibit
 - ▶ Smooth muscle hyperplasia
 - ▶ Mucus gland hyperplasia
 - ▶ Subepithelial fibrosis
- ▶ Decreased lymphocyte and myofibroblasts count in the airways after only eight weeks of Montelukast treatment
- ▶ Animal and human studies indicate that anti leukotrienes may prevent airway remodeling of goblet and smooth muscle cell hyperplasia and subepithelial fibrosis
- ▶ Long-term studies are needed to confirm the clinical outcomes of the anti remodeling effect of leukotriene receptor antagonist

ANTAGONIST LEUKOTRIENES (VERY PROMISING)



- ▶ Treatment with anti-immunoglobulin (Ig) E or (Omalizumab)
 - ▶ Reduces blood Ig E and decreases asthma symptoms
- ▶ Treatment with anti-IgE (e.g. omalizumab) significantly reduced both sputum and tissue eosinophilia as well as IgE-positive T and B cells
- ▶ Had very little effect on AHR in asthmatic patients
- ▶ Anti-IgE treatment has been shown to reduce levels of the circulating cytokines IL-5 and IL-13
- ▶ Improve lung function with moderate to severe allergic asthma requiring daily administration of corticosteroids
- ▶ Currently, little effect of anti-IgE treatment on the airway remodeling process has been reported

ANTI-IMMUNOGLOBULIN E (XOLAIR)



- ▶ Beta-2 agonists (Albuterol) reduces airway muscular tone and improve expiratory flows
- ▶ There is little evidence that beta-2 agonists affect airway remodeling
- ▶ One study by Orsida shown that Salmeterol with ICS can effectively reduce the number of vessels in their lamina propria compared with patients treated with corticosteroids alone
- ▶ Theophylline has no evidence supporting its influence on airway remodeling

BETA-2 AGONIST AND THEOPHYLLINE

- ▶ Inflammatory process remains the primary target of new drugs used in the future prevention and treatment of asthma
- ▶ Current therapies are not designed to specifically treat the underlying remodeling process
- ▶ Four treatment options are under investigation
 - ▶ Bacille Calmette-Guérin vaccines (vaccine for tuberculosis)
 - ▶ Capable of switching the immune response thus reducing inflammation and remodeling
 - ▶ IL-5 antibodies target eosinophil-mediated inflammation
 - ▶ Rapamycin, a macrolide analogue
 - ▶ Immunosuppressive effects and may influence inflammation and remodeling in experimental mouse models of asthma
 - ▶ Phosphodiesterase (PDE) inhibitors
 - ▶ Reported to have bronchodilatory, anti-inflammatory and potential anti-remodeling properties

THERAPIES UNDER INVESTIGATION



- ▶ Bronchothermoplasty is a novel mode of intervention that consists of applying an electric current to segmental and subsegmental bronchi
- ▶ Goal of destroying the smooth muscle reducing its capacity to contract
- ▶ Further studies are needed to determine the utility of this treatment but it has been shown to alter airway structure in a possibly beneficial way

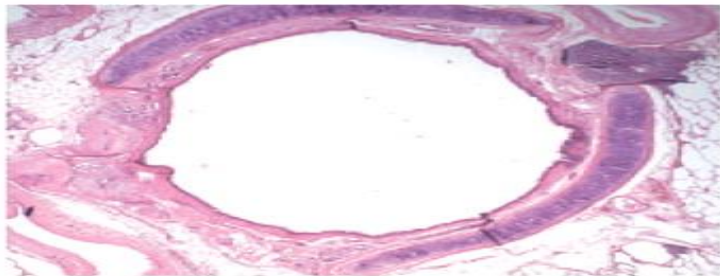
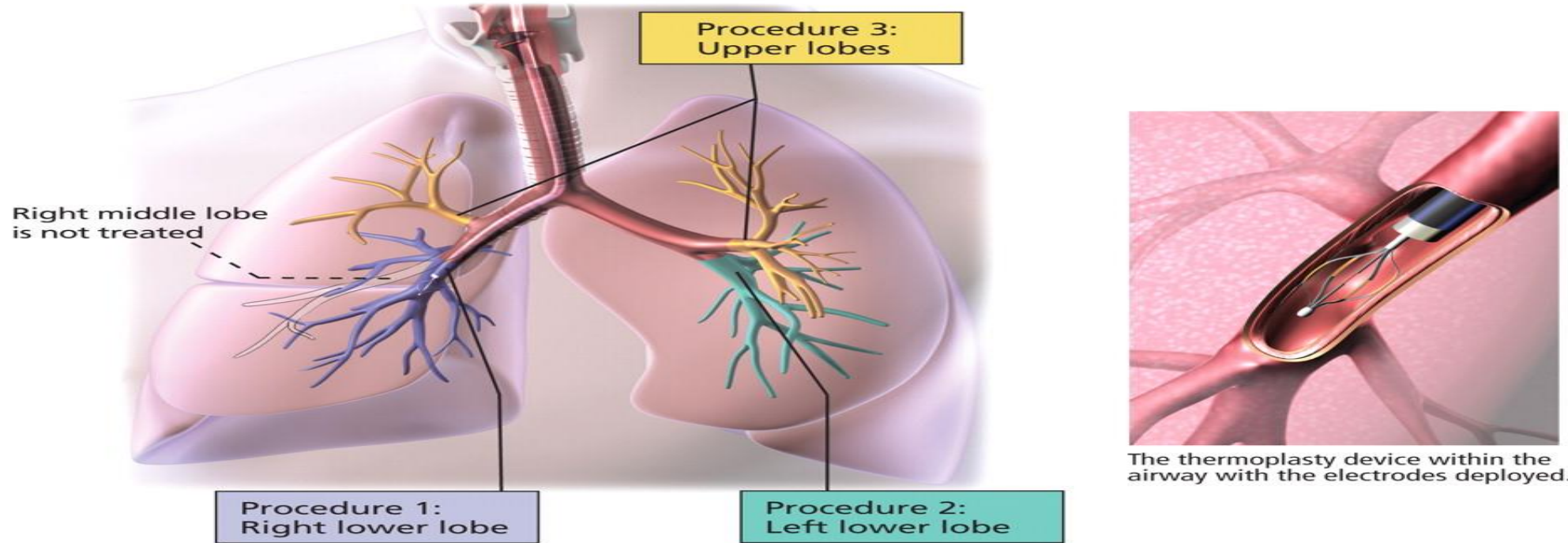
BRONCHOTHERMOPLASTY



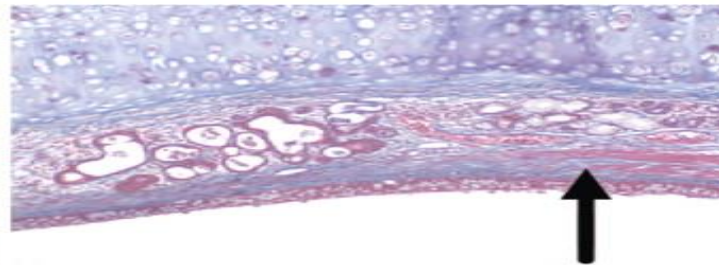
Bronchial thermoplasty for severe refractory asthma

Bronchial thermoplasty involves delivery of radiofrequency energy to the airway wall, which ablates the smooth muscle layer, lessening bronchoconstriction and improving symptoms.

Treatments are done in three separate procedures, with meticulous mapping of the areas treated. The right lower lobe is treated in the first procedure, the left lower lobe in the second, and the two upper lobes in the third. The right middle lobe is not treated.



Cross-sectional photograph of a treated airway from a patient with lung cancer resected 20 days after treatment. Magnification: 40x.

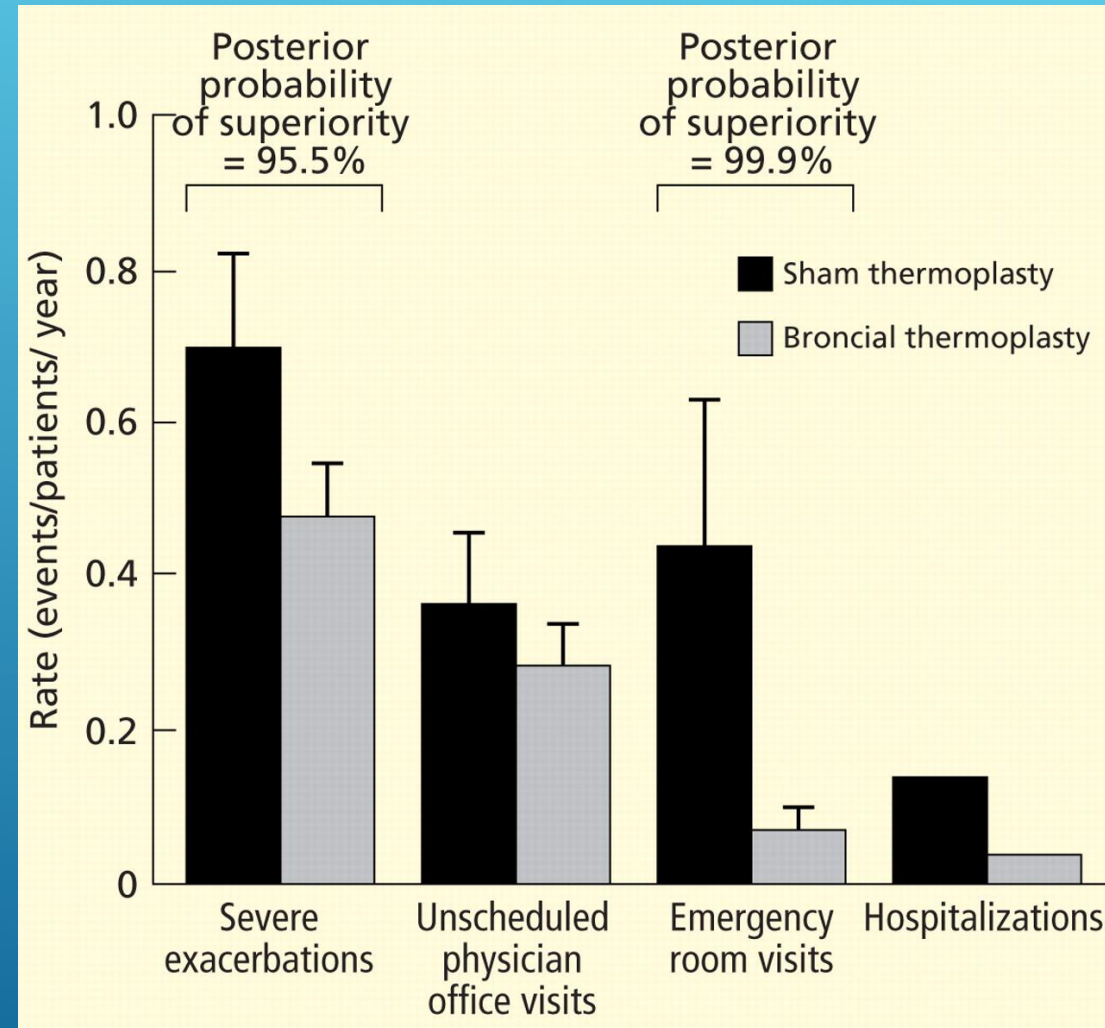


Trichrome-stained section at higher magnification (400x). Airway smooth muscle is largely absent to the left of the arrow.

PHOTOMICROGRAPHS FROM MILLER JD, COX G, VINCIC L, LOMBARD CM, LOOMAS BE, DANEK CJ. A PROSPECTIVE FEASIBILITY STUDY OF BRONCHIAL THERMOPLASTY IN THE HUMAN AIRWAY. CHEST 2005; 127:1999-2006. REPRODUCED WITH PERMISSION FROM THE AMERICAN COLLEGE OF CHEST PHYSICIANS.



The AIR2 trial: Effect of bronchial thermoplasty and sham thermoplasty on health care utilization
Health care utilization in the 12 months after real or sham thermoplasty.



- ▶ Hough, K. P., Curtiss, M. L., Blain, T. J., Liu, R. M., Trevor, J., Deshane, J. S., & Thannickal, V. J. (2020). Airway remodeling in asthma. *Frontiers in medicine*, 7, 191.
- ▶ Hsieh, A., Assadinia, N., & Hackett, T. L. (2023). Airway remodeling heterogeneity in asthma and its relationship to disease outcomes. *Frontiers in Physiology*, 14, 24.
- ▶ Kardas, G., Kuna, P., & Panek, M. (2020). Biological therapies of severe asthma and their possible effects on airway remodeling. *Frontiers in Immunology*, 11, 1134.
- ▶ Varricchi, G., Ferri, S., Pepys, J., Poto, R., Spadaro, G., Nappi, E., ... & Canonica, W. G. (2022). Biologics and airway remodeling in severe asthma. *Allergy*.

REFERENCES

